

CUSTOMFLEX® ARTIFICIALIRIS

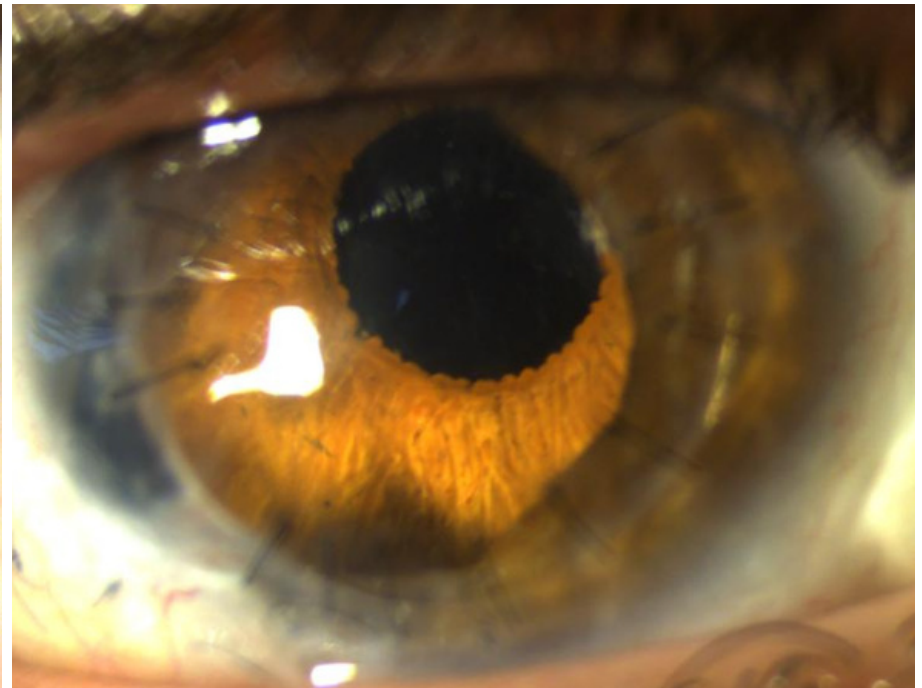
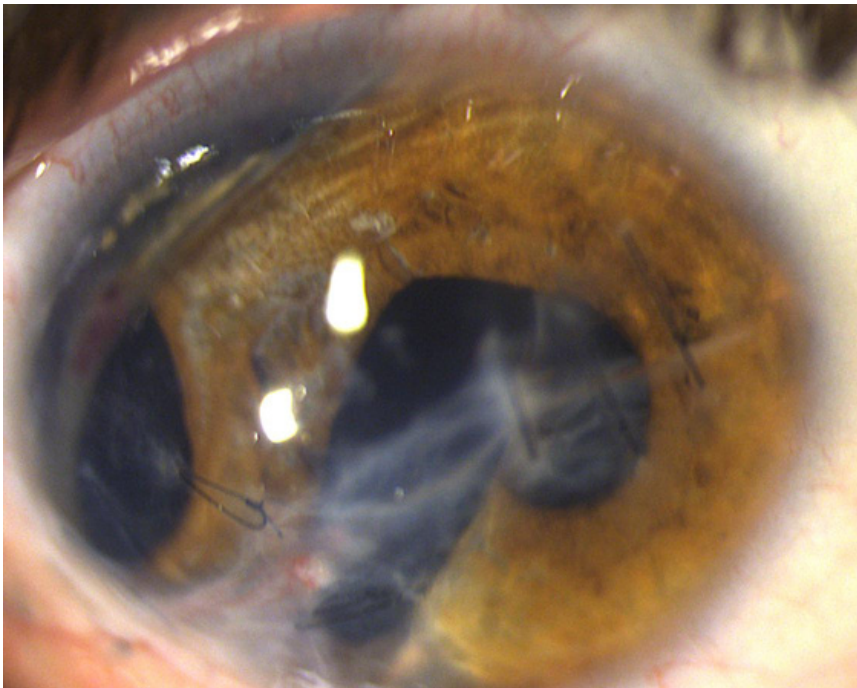
*Images and case provided courtesy of Sarah Weissbart, MD and Khurram Chaudhary, MD,
Stony Brook University*

VeoOphthalmics
**CASE
OF THE
MONTH**
August 2022

23 y/o man with history of a full thickness corneoscleral laceration with vitreous & uveal prolapse, iridodialysis, and traumatic cataract in 2021. Patient subsequently underwent pars plana vitrectomy/lensectomy but remained with significant iridodialysis and a large central corneal scar.

Due to poor vision and significant glare symptoms, the patient had a scleral sutured CUSTOMFLEX® ARTIFICIALIRIS (with fiber) and IOL implanted, along with a penetrating keratoplasty.

The patient noted improvement in glare and cosmesis, though his visual acuity was limited by a significant ERM, for which he recently underwent a pars plana vitrectomy and membrane peel.



To submit your case, please email ggravino@veo-ophthalmics.com