


CUSTOMFLEX® ARTIFICIALIRIS

Case and Images provided courtesy of Winston Chamberlain, MD, PhD, Casey Eye Institute at Oregon Health & Science University

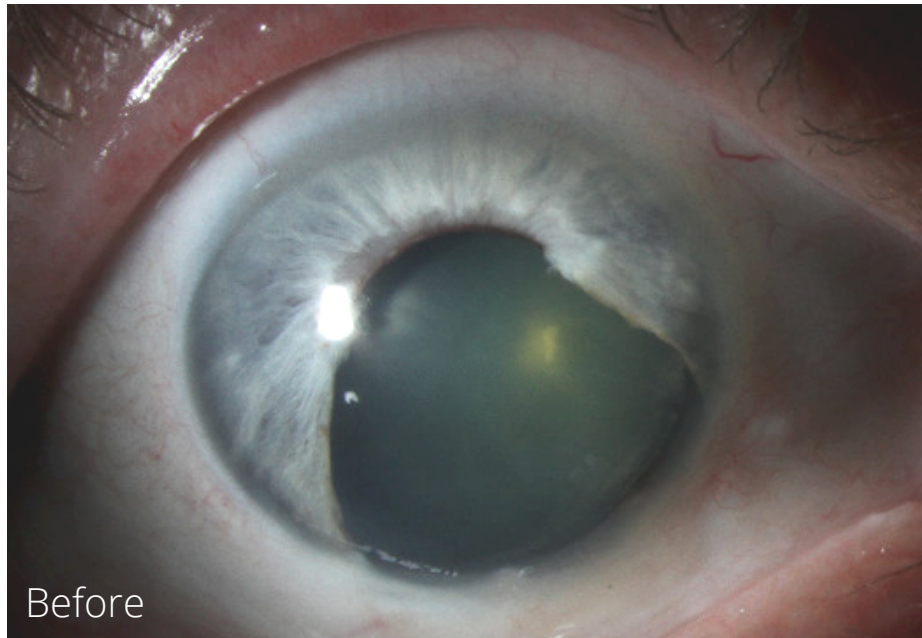

Patient's History:

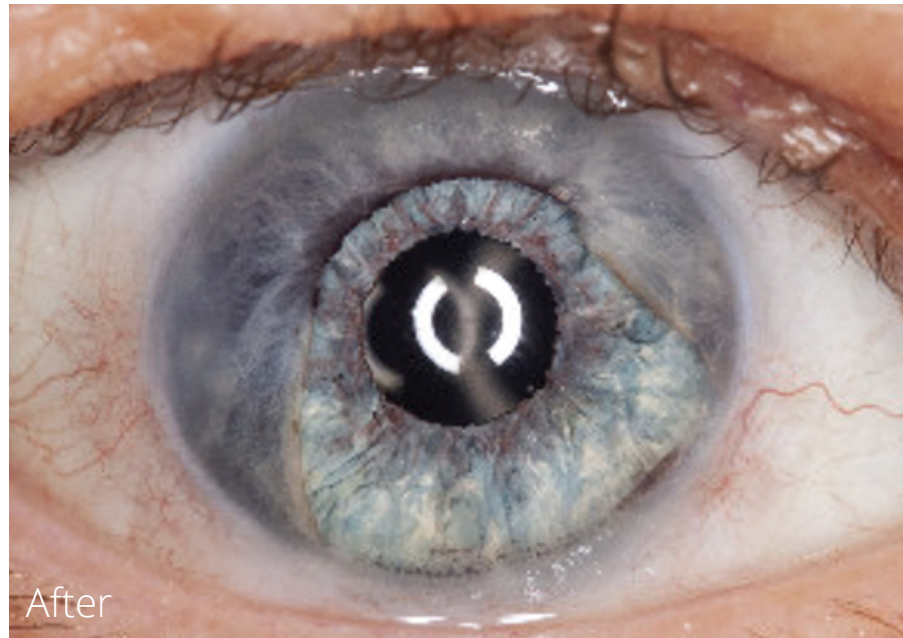
- h/o malignant melanoma in right iris resected 50 years ago
- 4-5 clock hours of missing iris, right eye
- Intractable light/glare for decades
- Nuclear cataract and missing zonules in sight of previous resection, right eye
- Visual acuity 20/30 in dark but 20/100 with direct illumination

Implantation/Post-Op Results:

- Underwent cataract extraction, placement of 3 piece IOL, Capsular tension ring and trephined CUSTOMFLEX® ARTIFICIALIRIS, all placed in capsular bag
- 1 month follow up had complete resolution of glare and 20/20 visual acuity



Before



After