

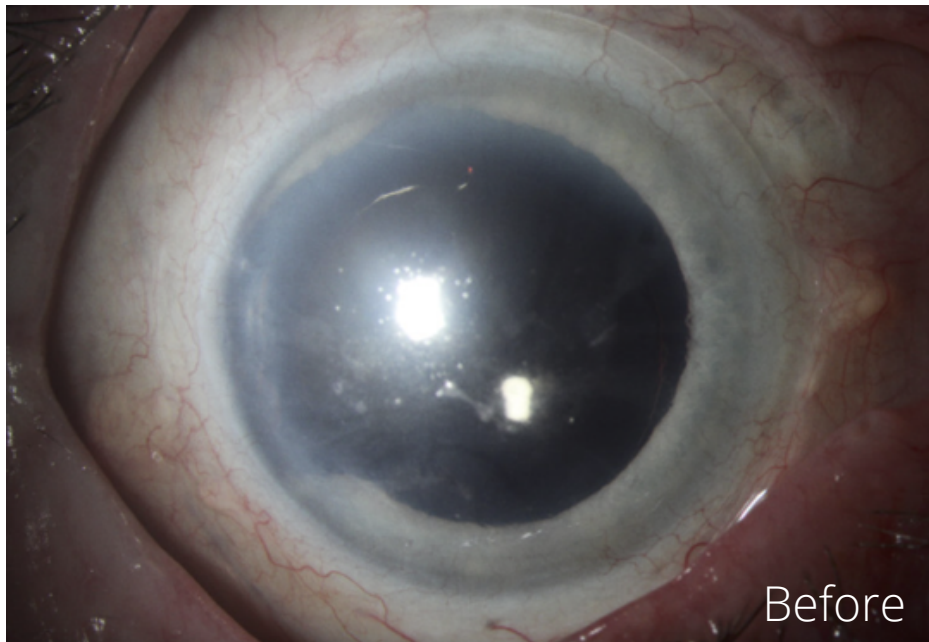
CUSTOMFLEX® ARTIFICIALIRIS

Images and case provided courtesy of Winston Chamberlain, MD, PhD, Casey Eye Institute at Oregon Health & Science University

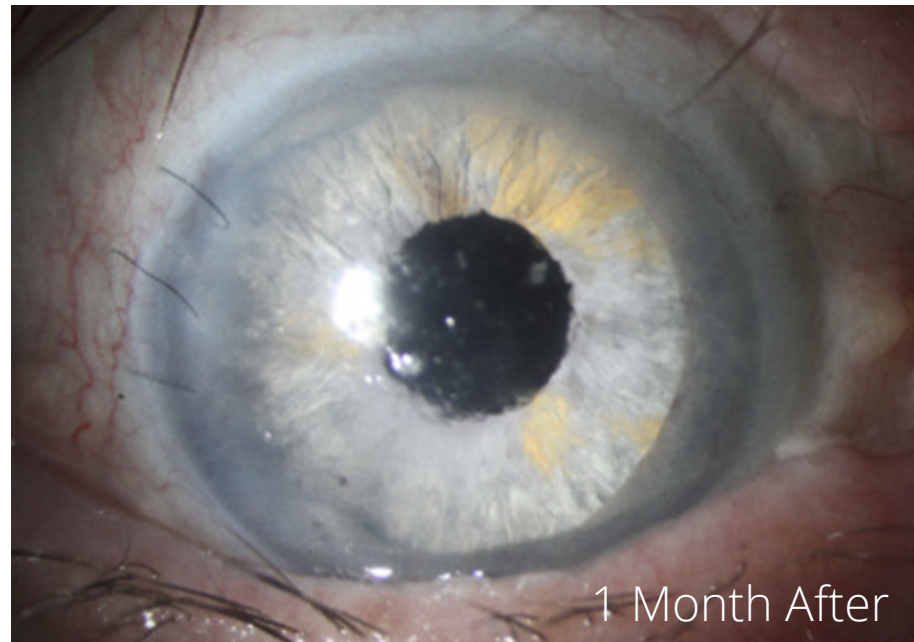


73-year-old male with a complex ocular history

- 1/2015: Traumatic Injury - ruptured globe right s/p repair (full thickness corneal defect plugged by iris, dislocated lens)
- 4/2015: S/p pars plana lensectomy + scleral sutured IOL (CZ70BD)
 - Attempted iris repair, however iris atrophic and unable to hold prolene stitch
- 5/2015: S/p sutured amniotic membrane graft with right permanent tarsorrhaphy for exposure K, re-opened
- 11/2017: S/p RUL entropion repair
- 4/2021: Implanted CUSTOMFLEX® ARTIFICIALIRIS. Patient went from counting fingers vision to 20/100 vision. All of his glare and photophobia is resolved in the surgical eye.



Before



1 Month After