


CUSTOMFLEX® ARTIFICIALIRIS

Case provided courtesy of Steven G. Safran, M.D, P.A., Lawrenceville, NJ.

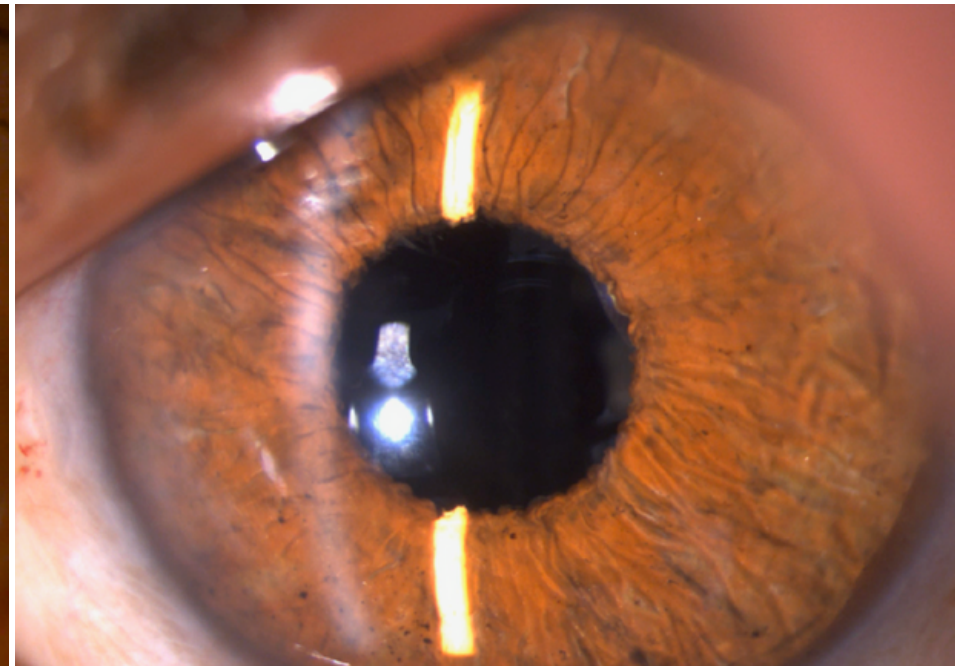
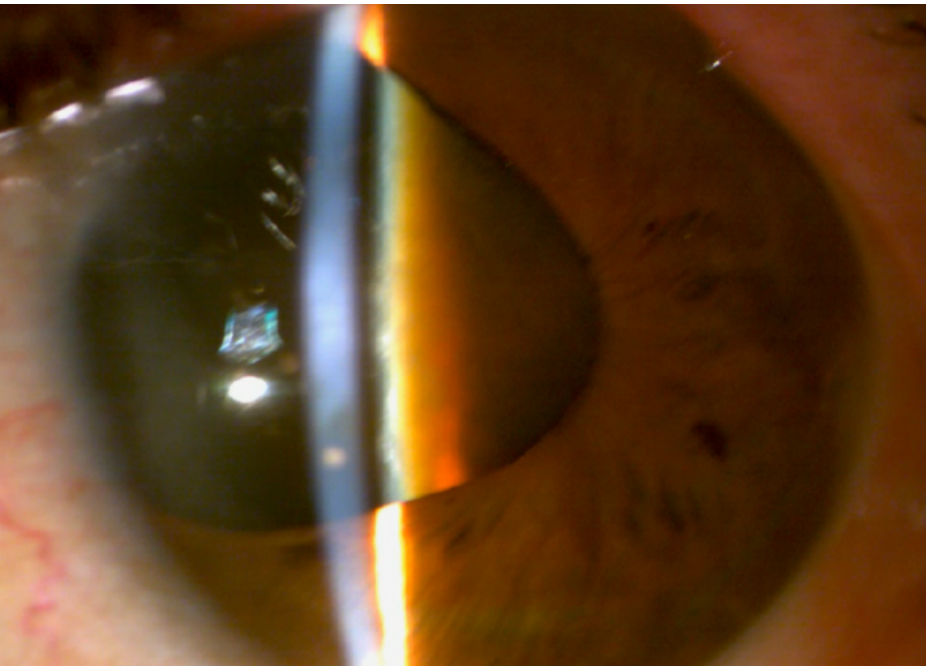


70 y/o male who had trauma as a child and has not seen out of this eye since then. He is referred with a large iris defect, a brunescant cataract, a large area of missing zonules and phacodonesis. The plan was to do phacoemulsification and place an IOL and CUSTOMFLEX® ARTIFICIALIRIS in the capsular bag.

The phacoemulsification was performed with capsular support and a CTR placed in the intact capsular bag. While suturing the CTR in place, the trailing end of the Goretex suture cuts the edge of the anterior capsule as it's being pulled through the sclerotomy, causing a radial tear. An alternate strategy of suturing a CZ70BD and the CUSTOMFLEX® ARTIFICIALIRIS separately in combination with a Pars Plana vitrectomy is pursued successfully. The patient did very well with 20/40 uncorrected vision refracting to 20/25 at 5 weeks.



**Surgical Video
provided**



To submit your case, please contact 513-872-1330 or ggravino@veo-ophthalmics.com