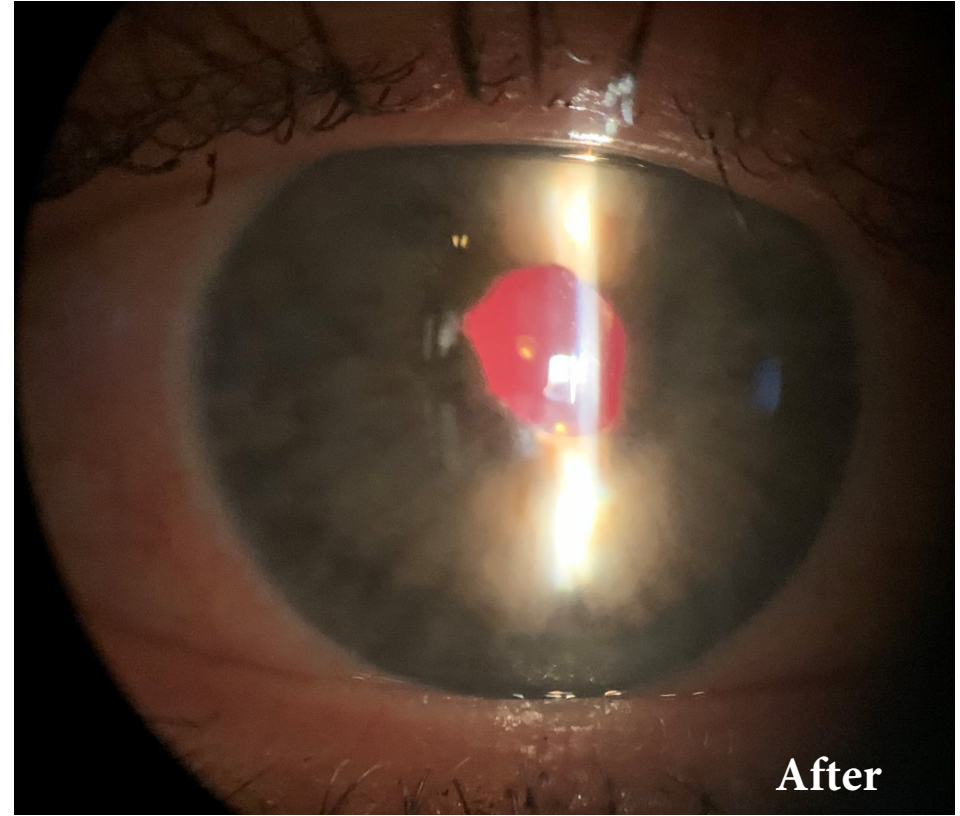
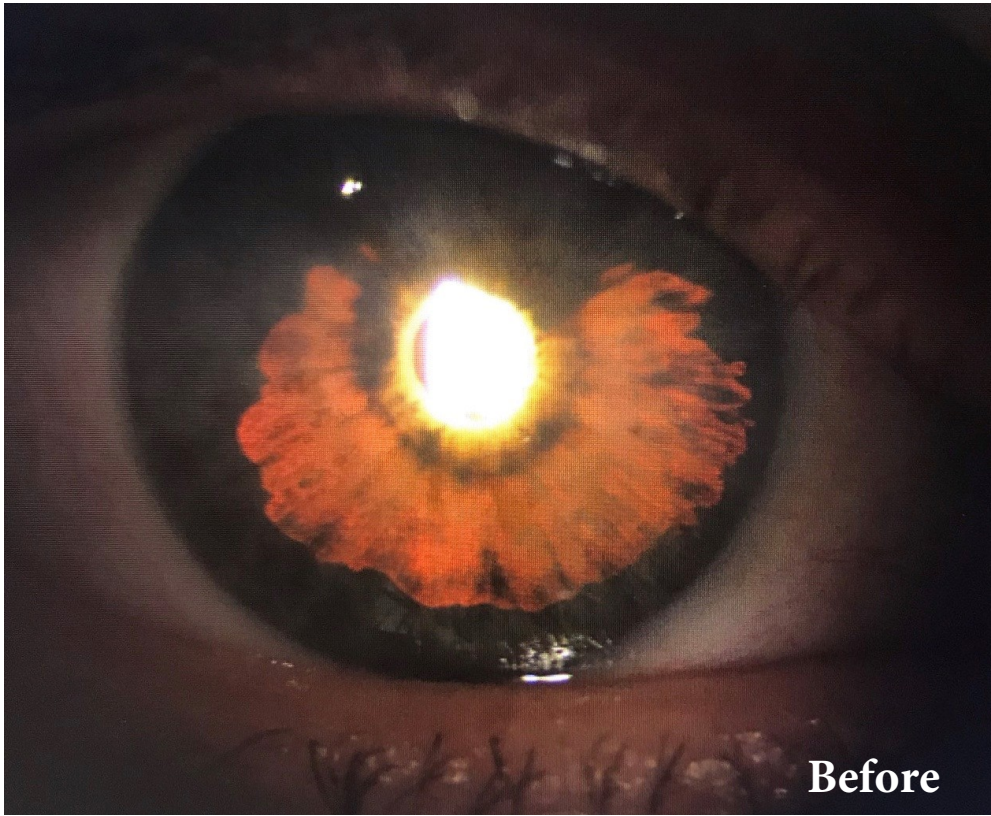

CUSTOMFLEX[®] ARTIFICIALIRIS: Photo of the Month



A 65-year-old woman presented with a chief complaint of significant photophobia and blurry vision in her right eye. Her ocular history included a visually significant cataract and iritis in the right eye, creating significant transillumination defects (See "Before" Image). Her best corrected vision was 20/60-2.

Following cataract extraction, placement of CUSTOMFLEX[®] ARTIFICIALIRIS (See "After" Image), and a monofocal IOL, her best corrected vision is 20/20; and, she no longer suffers from the debilitating photophobia she experienced preoperatively.

Images and case provided courtesy of John Berdahl, MD and Justin Schweitzer, OD at Vance Thompson Vision.



To submit your case, please
contact us at:

513-872-1330
schristensen@veo-ophthalmics.com