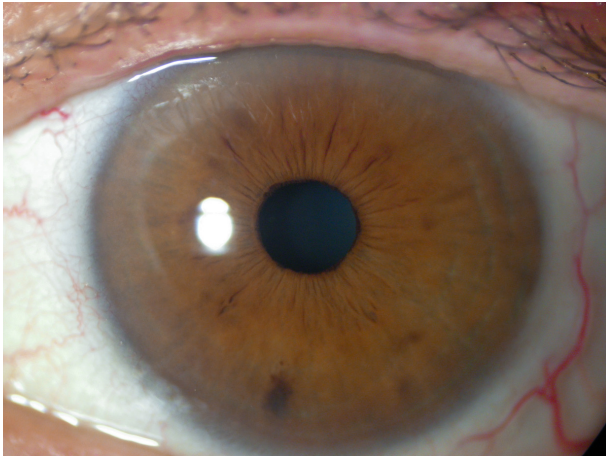


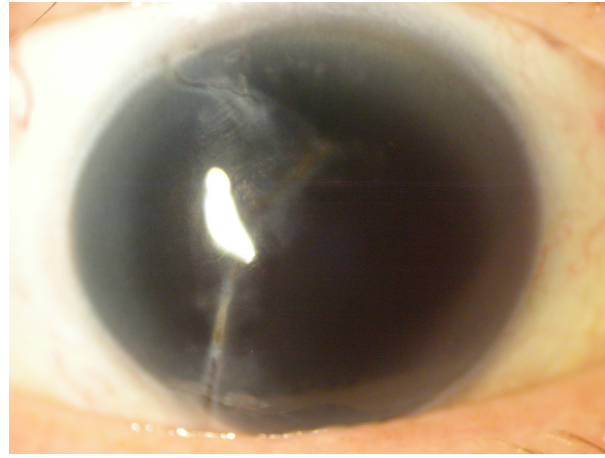
CUSTOMFLEX® ARTIFICIALIRIS: Photo of the Month - June 2019

James Lehmann MD



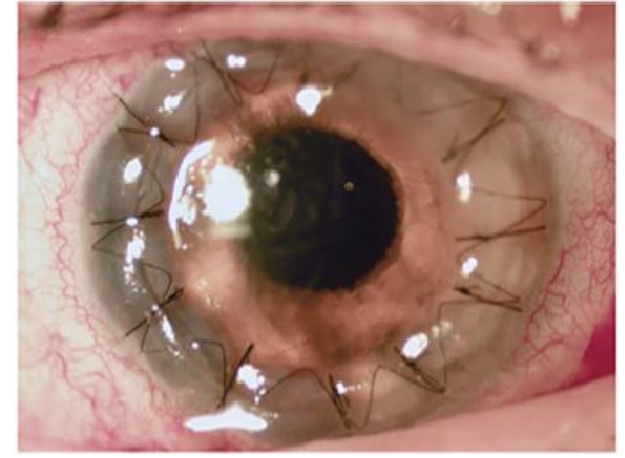
Pre-Op OS

Photo of the fellow eye used as a template for manufacture of the CUSTOMFLEX®ARTIFICIALIRIS.



Pre-Op OD

71 y.o. with history of penetrating trauma, vitrectomy, lensectomy, and corneal laceration repair; has worn a black patch for the past 20 years due to glare.



Post-Op OD

One day post-op after sutured IOL/ CUSTOMFLEX®ARTIFICIALIRIS and penetrating keratoplasty, distance vision 20/150. At one month post-op, pinhole vision 20/50; happy with appearance and vision.



James Lehmann, MD is a Cornea, Cataract and Refractive Surgeon in private practice in San Antonio, Texas. He is adjunct faculty at UT Health San Antonio and is a former ORBIS staff ophthalmologist.

