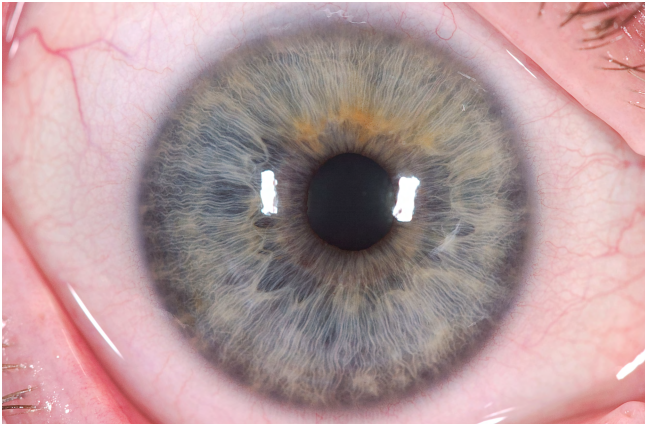


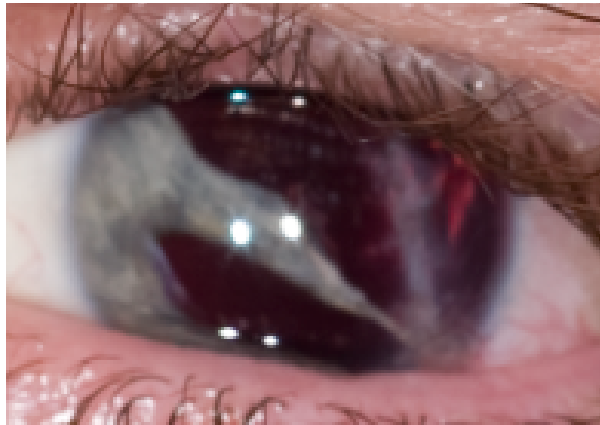
# CUSTOMFLEX® ARTIFICIALIRIS: Photo of the Month - March 2019

KEVIN M. MILLER MD



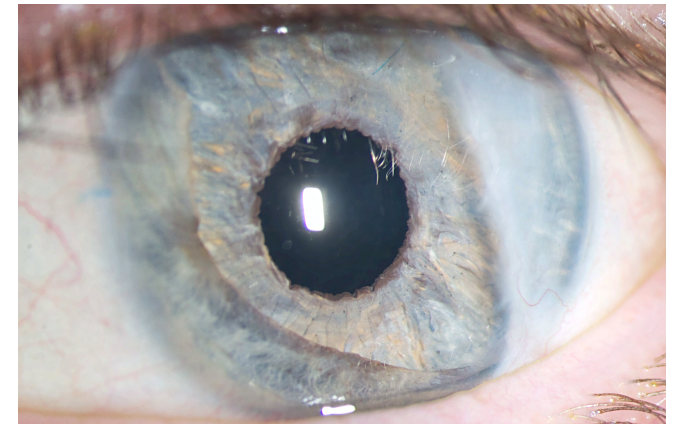
Pre-Op OD

Photo used as template for manufacture of the CUSTOMFLEX®ARTIFICIALIRIS.




Pre-Op OS

45 y. o. Broken glass bottle injury to left eye, lacerated cornea, iris, and lens capsule. Corrected distance visual acuity 20/150 at time of preoperative photo.



Post-Op OS

Corrected distance visual acuity at 3-month post-op was 20/30 +2 and at 1-year post-op was 20/15 -2; 1-year post-op uncorrected distance visual acuity was 20/20 -2. Patient reported that light and glare sensitivity were resolved.



Dr. Miller is the Kolokotronis Chair in Ophthalmology, Chief of the Cataract and Refractive Surgery Division, and Director of the Anterior Segment Diagnostic Laboratory at Stein Eye Institute and Department of Ophthalmology at the David Geffen School of Medicine at UCLA.

