

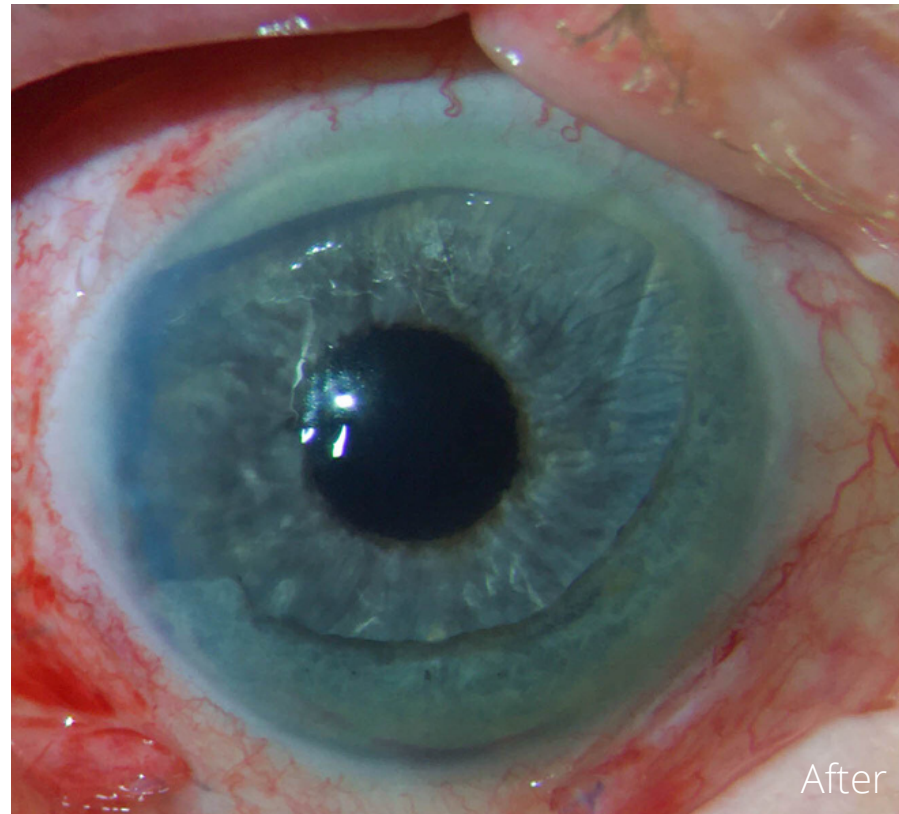
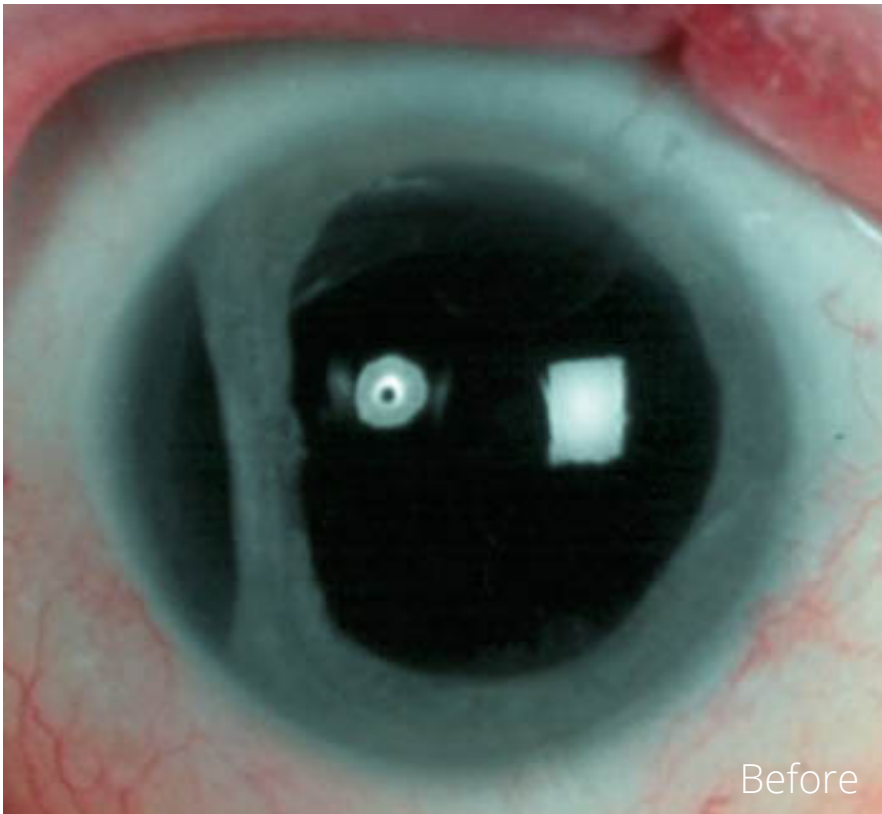
# CUSTOMFLEX® ARTIFICIALIRIS

Case and Images provided courtesy of Dr. Richard Hoffman, Drs. Fine, Hoffman & Sims, Eugene, OR

**VeoOphthalmics**  
**CASE  
OF THE  
MONTH**  
December 2021

.....

A 74 y.o. male with a history of a chain saw accident, which caused traumatic cataract, phacodonesis, iridodialysis, vitreous in the AC and a partial thickness corneal laceration OD, underwent a vitrectomy and lensectomy 5 years ago. Pre-op vision was CF with severe photosensitivity, necessitating fulltime sunglasses. Two months following implantation of the CUSTOMFLEX® ARTIFICIALIRIS with a secondary IOL attached, BCVA 20/30- with resolved photophobia.



To submit your case, please contact 513-872-1330 or [ggravino@veo-ophthalmics.com](mailto:ggravino@veo-ophthalmics.com)