

CUSTOMFLEX® ARTIFICIALIRIS

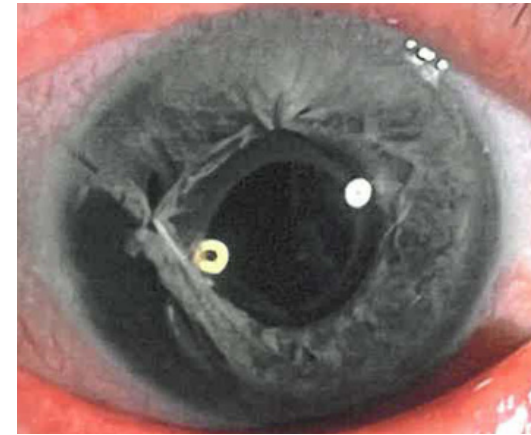
Images and case provided courtesy of Michael Brush, MD, Kaiser Permanente



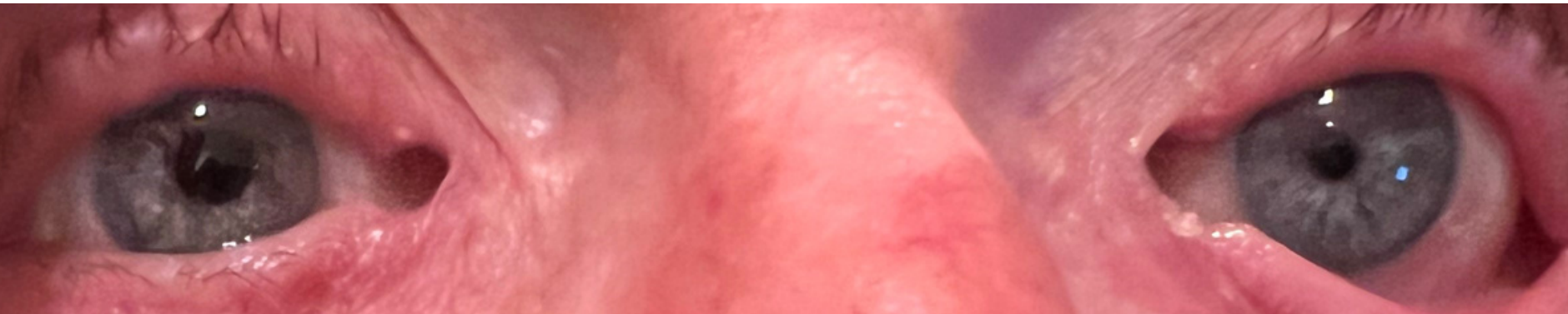74 y/o man with history of chronic angle closure glaucoma s/p laser peripheral iridotomy. In 2020 he underwent cataract surgery OD that had to be aborted due to severe iris prolapse even with placement of Malyugin ring. Patient on Flomax with very shallow anterior chamber. 4 days later he underwent pars plana vitrectomy and cataract surgery but was left with significant iris damage – between 5 and 10 o'clock.

Due to significant glare symptoms he underwent suture iris repair in 2021, which did not improve his symptoms. In 2022, he had the CUSTOMFLEX® ARTIFICIALIRIS (with fiber) implanted in the sulcus, and due to adequate residual tissue, it was not suture fixated.

At the one month visit the patient has the same uncorrected visual acuity (20/40) but with improvement in his significant glare symptoms.



Pre-Op Photo



Post Op Bridge Photo

To submit your case, please email ggravino@veo-ophthalmics.com