

CUSTOMFLEX® ARTIFICIALIRIS

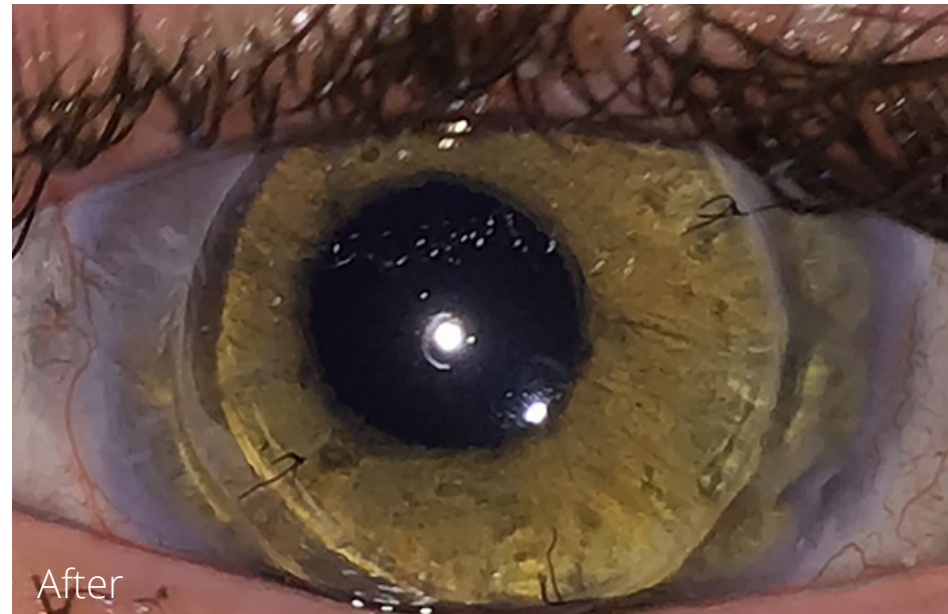
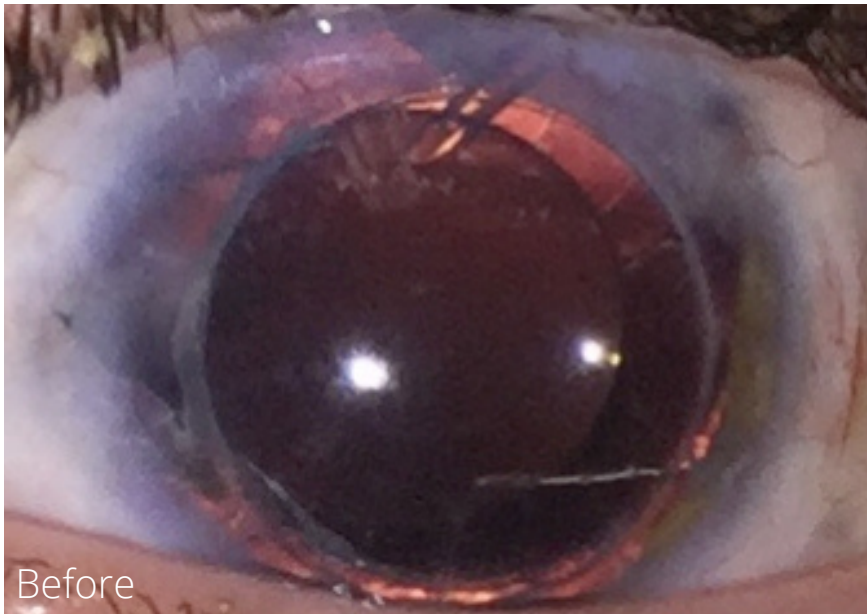Case and Images provided courtesy of Rahul Tonk, MD, Bascom Palmer Eye Institute

VeoOphthalmics
**CASE
OF THE
MONTH**

March 2022

Our patient is a 25 year old male with an unfortunate penetrating injury from a screwdriver to the left eye. The patient underwent several staged surgeries, including laceration repair, cataract extraction, pars plana vitrectomy with scleral sutured intraocular lens, penetrating keratoplasty, and Ahmed glaucoma drainage device implantation.

Following these surgeries, he achieved a BCVA of 20/40 but found the eye “unusable” due to intractable glare and light sensitivity. Three months following implantation of the CUSTOMFLEX® ARTIFICIALIRIS, he has a BCVA of 20/20- and is fully functional with glasses.



To submit your case, please contact 513-872-1330 or ggravino@veo-ophthalmics.com