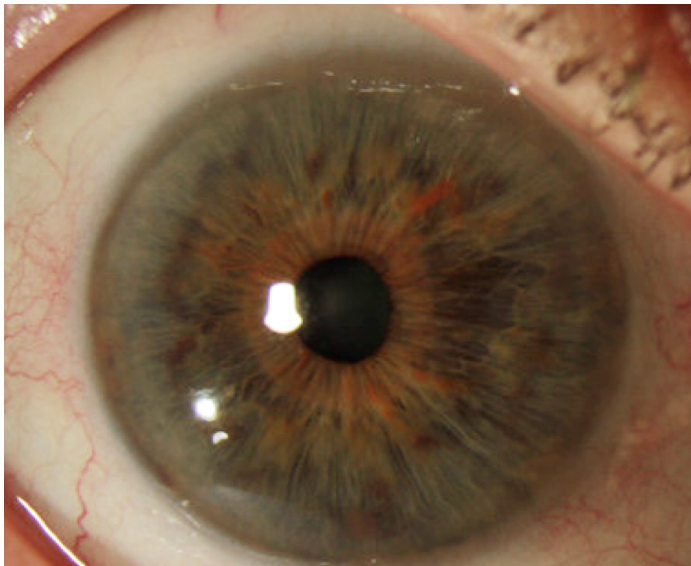


CUSTOMFLEX® ARTIFICIALIRIS: Photo of the Month - February 2019

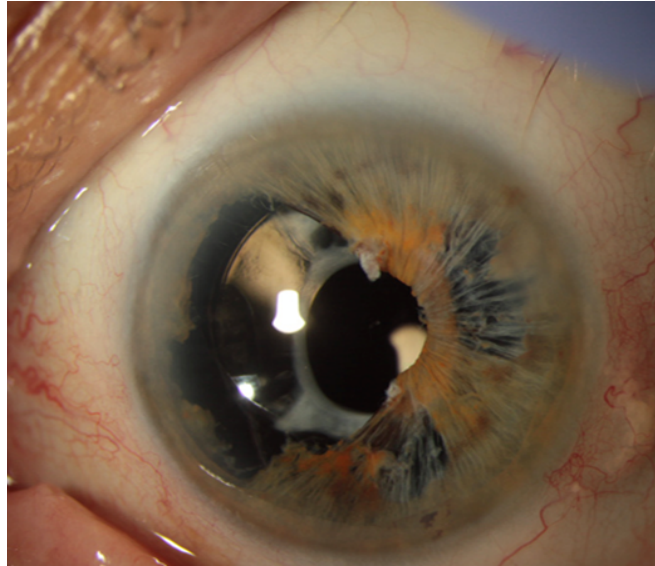
KAROLINNE MAIA ROCHA MD, PHD

LARISSA GOUVEA MD



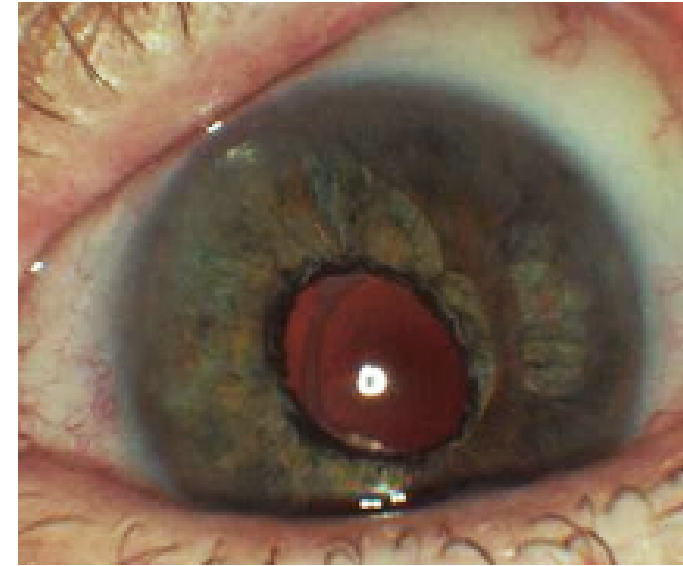
Pre-Op OD

Photo used as template for manufacture of the CUSTOMFLEX® ARTIFICIALIRIS.



Pre-Op OS

IFIS related iris defect after cataract surgery causing severe photophobia, necessitating opaque periphery contact lens for function.



Post-Op OS

Photophobia resolved with CUSTOMFLEX® ARTIFICIALIRIS behind the residual iris in the ciliary sulcus.



Dr. Rocha is the Director of Cornea & Refractive Surgery, Storm Eye Institute, Medical University of South Carolina (MUSC). She is seen here with her surgical team.

