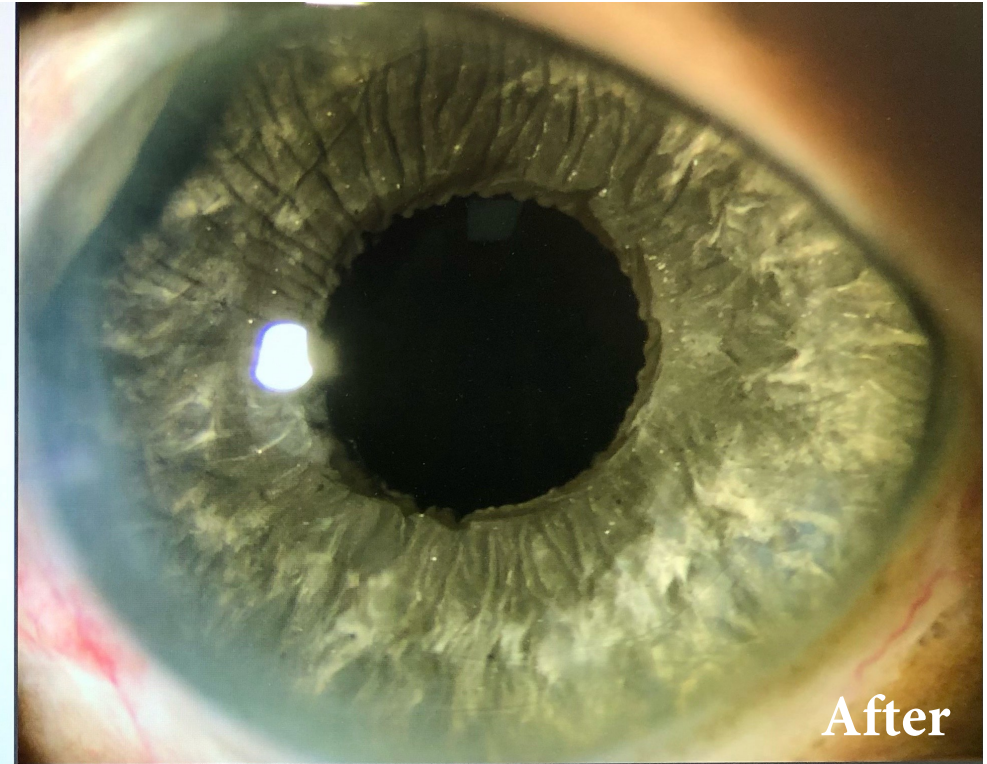
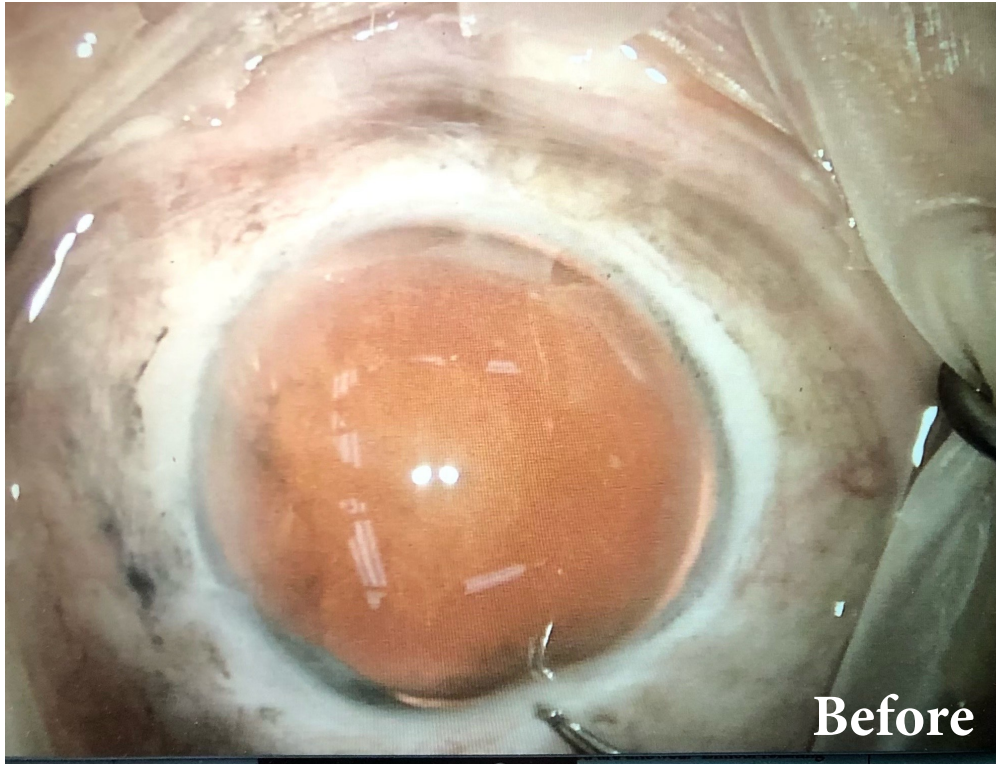


CUSTOMFLEX[®] ARTIFICIALIRIS: Photo of the Month

March 2021



A 69-year-old woman presented with a chief complaint of blurry vision and photophobia of the right eye. Her ocular history included an open globe injury which left her aniridic. She also had a visually significant cataract. Her best corrected vision was 20/400.

Following cataract extraction, placement of the CUSTOMFLEX[®] ARTIFICIALIRIS, and a monofocal IOL, her best corrected vision is 20/20; and, she no longer suffers from photophobia.

Images and case provided courtesy of Mike Greenwood, MD
at Vance Thompson Vision



To submit your case, please
contact us at:

513-872-1330
schristensen@veo-ophthalmics.com